
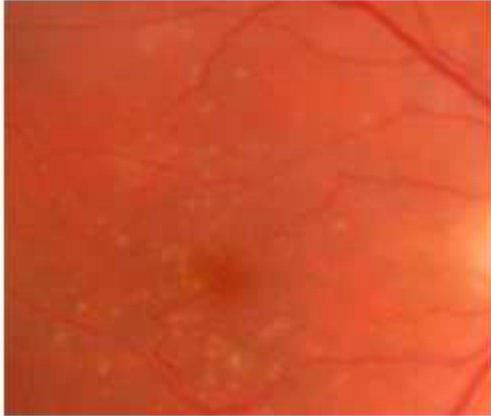


DRUSEN

Derived from German Mineralogy word describing speckles in Stone.



Above one can see the typical yellow spots at the back of the eye in the retina. This is the film of the camera and does all the seeing. These white spots on the left eye can be seen as little raised areas scattered at random on the back of the eye. Everyone's drusen form a different pattern like seeds scattered on the back of the eye.

I view them as the "waste products of the eye" that cannot be removed and they build up just like the rubbish outside ones house.

Over many years they sometimes can disappear, often then leaving a little dry Macular degeneration in its place.

Generally there is no treatment for this, but it can be the precursor of Dry or Wet Age related macular degeneration.


Retinal Pigment Epithelium cells continuously ingest photoreceptor outer segments that are shed throughout life. The residue of intracellular digestion may eventually fill the cell. The earliest clinical sign of Age Related Macular Degeneration is the development of drusen, which are extracellular deposits that lie between the basement membrane of the retinal pigment epithelium and the inner collagenous zone of Bruch's membrane. It has been suggested that apoptosis, a process by which cells cast off a part of their cytoplasm, may lead to drusen formation.

Drusen vary in size, shape, color, consistency, and distribution, although they are often bilaterally symmetric, clustered in the macular region, and tend to increase in number with advancing age.

Histopathologically, retinal receptors overlying drusen usually show minimal evidence of degeneration, and, therefore, most patients with drusen have excellent vision and are asymptomatic. However, some patients with central drusen complain of mild metamorphopsia and decreased ability to read. Histochemically, drusen contain sialic acid and cerebroside. Drusen can be classified as one of several types: (1) hard (nodular), (2) soft, (3) calcified, or (4) basal laminar.

HARD DRUSEN

Hard drusen are small, round, discrete punctate nodules. They are believed to develop by the shedding of basal cytoplasm of Retinal Pigment Epithelium through its basement membrane. The material in hard drusen resembles the components of aging Bruch's membrane, containing coated, membrane bound bodies, membrane fragments, vesicles, and granular material. Hard drusen are probably the consequence of extrusion of material from one or a cluster of Retinal Pigment Epithelium cells. Dominant drusen refers to a dystrophy in which excessive

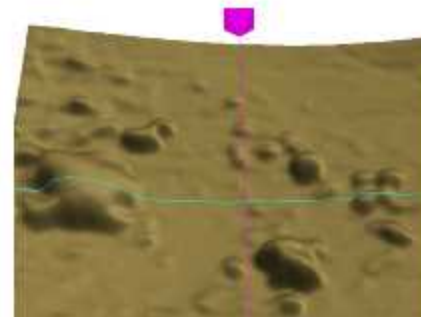


numbers of hard drusen are seen in the macular area of younger patients. They tend to be bilaterally symmetric. These patients may be at increased risk for the development of SRNV later in life.

SOFT DRUSEN

Soft drusen are large, pale-yellow or gray, dome-shaped, occasionally confluent structures with indistinct margins. The material within the drusen is located beneath the Retinal Pigment Epithelium and may appear homogeneous and hyalinized, granular, or a combination of both. Soft drusen vary greatly in size and shape and are indicators of a general decline in cellular function. Clinically, angiographically, and histopathologically they appear identical to pigment epithelial detachments. Soft drusen have the poorest prognosis of all drusen.

One can see the large soft drusen in the Left of this RPE OCT scan.



Natural history of drusenoid pigment epithelial detachment in age-related macular degeneration: Age-Related Eye Disease Study Report No. 28.

Cukras C, Agrón E, Klein ML et al.

National Institutes of Health, Bethesda, MD, USA.

Ophthalmology 2010;117:489–99.

Editor's note: This is another study from the AREDS (Age-Related Eye Disease Study) cohort. Of 4757 patients enrolled in AREDS, 255 were identified as having drusenoid pigment epithelial detachment (PED) in at least one eye and ≥ 5 years of follow-up.

Drusenoid PED was defined as a fairly well-circumscribed, shallow elevation of the retinal pigment epithelium formed by a confluence of soft drusen, often located in the central macula. After 5 years of follow-up, advanced age-related macular degeneration (AMD) developed in 42%, with 19% progressing to central geographic atrophy and 23% progressing to neovascular AMD. Other aspects noted were progression to calcified drusen and pigmentary changes. Overall, 40% of eyes experienced reduction in visual acuity (VA) by ≥ 15 letters, with the mean VA decreasing from 76 letters at baseline to 61 letters at 5 years.

CALCIFIED (REGRESSING) DRUSEN

With time, drusen change in size, shape, distribution, color, and consistency. They may fade and disappear, or they may lead to localized areas of atrophy of the Retinal Pigment Epithelium. Once the Retinal Pigment Epithelium overlying the drusen fails, the drusen start to regress, assuming a whiter and harder appearance. This may be associated with pigmentary stippling. Some drusen become filled with cholesterol crystals and present a sparkling appearance. They may become calcified as well as atrophic. Ultimately, drusen fade completely to leave multifocal patches of atrophy, although glistening calcium deposits may remain for years.⁷

BASAL LAMINAR DRUSEN

Bruch's membrane consists of five layers, the innermost being the pigment epithelial basement membrane, also called the basal lamina or cuticular layer. Hard and soft drusen cause a separation of the pigment epithelial basement membrane from the inner collagenous portion of Bruch's membrane. Basal laminar or cuticular drusen are focal thickenings of the basement membrane of the Retinal Pigment Epithelium. Although not impressive on clinical examination, these basal laminar drusen present a striking fluorescein angiographic picture of innumerable uniform, small, slightly raised, yellow nodules. Basal laminar drusen fluoresce early during angiography, corresponding to focal areas of Retinal Pigment Epithelium attenuation overlying the nodular thickenings.

PERIPHERAL DRUSEN

Although drusen are most commonly found in the macular region, they may be present anywhere in the fundus. Peripheral drusen are often surrounded by rings of pigment. This pigmentation may be confluent, linear, or radiating, producing a reticular pattern referred to as senile reticular pigmentary degeneration.

There is a strong correlation between peripheral drusen and pigmentation and the macular changes of Age Related Macular Degeneration.

Treatment

It is not possible to remove the Drusen but the concern is that this may lead to age related Macular degeneration. There is a great deal of interest in antioxidant multivitamins for age related Macular degeneration in its early phase. Many people do take a selection of antioxidants to increase the antioxidant level within the retina in the belief that the free radicals that are released when light enters the eye and meets the photo receptors are more quickly dealt with and thus do not produce damage to the photo receptors of the eye. I recommend to all of my patients with age related Macular degeneration to take additional vitamin supplementation.

Age Related Macular Degeneration

Vitamin Supplementation –

3 Types acting at different levels

1. Retinal Photoreceptor Protection

Results from the long-anticipated AREDS study, published in the October 2001 issue of Archives of Ophthalmology, show that taking supplements containing high levels of antioxidants and zinc significantly reduced the risk of advanced age-related macular degeneration (AMD).

This study has now been extended to 10 years continued benefit, and a second study is under way.

AREDS II will report in 2013 and is looking at the benefit Omega3 and Lutein addition to the PreserVision Vitamins.

Minimum Protection is: OcuVite PreserVision

Original Gels two a day is recommended for Age Macular Degeneration. (Not for smokers who should use Lutein Gels.

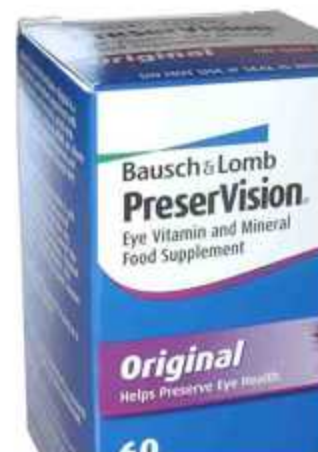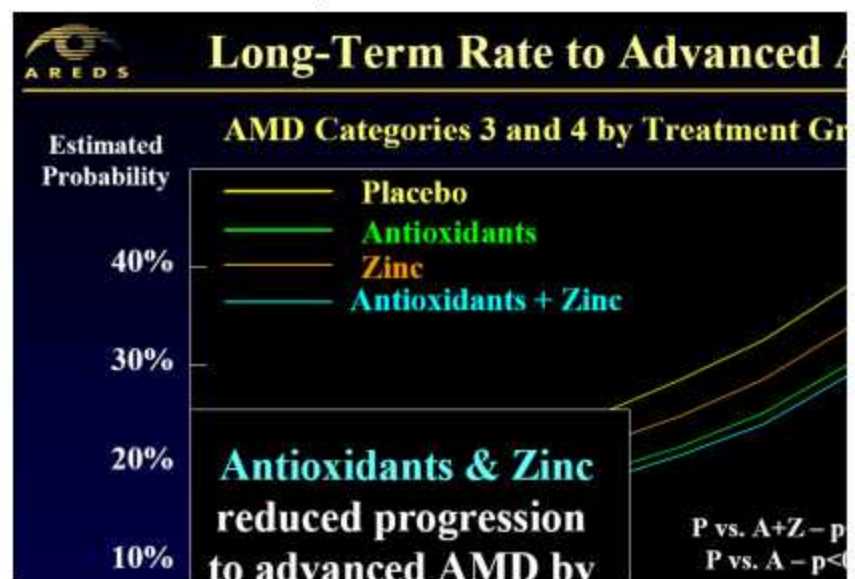
Available from Chemists or on line from eg.

www.chemistdirect.co.uk 0845 259 0175 Price around £14.00 is typical.

A Recent Royal College Of Ophthalmology Focus report recommends the use of AREDS Vitamin formulation ie OcuVite PreserVision.

Consider the following two as well.

2. OMEGA 3 Fish oils – Anti-Inflammatory



with

for

Related OcuVite

Increasingly interest in this area at present. These fatty acids are mainly found in fish and nuts. These fatty acids have anti-inflammatory properties and may be anti-angiogenic, which may mean that they protect against the formation of the new blood vessels found in the wet form of AMD. A number of studies have found a reduced risk of AMD in patients who have diets rich in omega-3 poly-unsaturated fatty acids. For instance in the AREDS study there was a fifty percent reduction in advanced AMD for the group who had the highest intakes compared to the group who had the lowest. It didn't take much of the omega 3 poly-unsaturated fatty acids to be effective because the highest intake group on average ate only one serving of broiled or baked fish a week. The National Eye Institute's AREDS 2 trial will also test if supplementation with omega 3 poly-unsaturated fats reduces the progression of Age Related Macular Degeneration



It will be a few years before we know the result. However it may be appropriate to take 1000mg of Omega-3 Oils in tablet form, as well as a diet rich in oily fish (Mackerel, sardines, Anchovies and Tuna). These can be bought cheaply from Chemist Direct (0845 259 0175) at 1.89 per bottle, or at local health food shops.

Do not however use Cod Liver oil as this contains vitamin A as well which you may well be taking in PreserVision Original Gels.

For Vegetarians there is Omega 3 From Flaxseed oil from Healthspan.co.uk on 0800 73 123 77

3. Lutein – Natural sunglasses

In addition Lutein 10mg & 2mg zeaxanthin is included in the AREDS II trial as well and is worth taking for maximal vitamin protection until we know the results of the trial.

Macushield is a Lutein and Zeoxanthein containing vitamin currently undergoing randomized trials. It has been shown to increase the levels in the blood stream. There has been recent publicity in the press over it.

It is a good source of Lutein and may be used in conjunction with PreserVision Original.

a unique supplement to support eye health

MACU SHIELD WITH MZ

Contains Meso-Zeaxanthin, the only carotenoid found exclusively in the macula

ABOUT CARRIER DEFENDANT

SOURCES OF LUTEIN & ZEAXANTHIN

LINKS

Home Page **Contact Us**

MacuShield is a unique carotenoid eye supplement
research institutions and endorsed by eye care

Scientists have long known that the yellow colour, or pigment, inside the macula comes from the carotenoids, lutein, zeaxanthin, and meso-zeaxanthin and believe these plant compounds help protect the eye by absorbing blue light and neutralising free radicals.

The patented blend brings together all three of these carotenoids (meso-zeaxanthin, lutein & zeaxanthin) to help maintain eye health throughout our later years.

...MORE

MESO-ZEAXANTHIN FORMULA

Meso-zeaxanthin (10mg), Lutein (10mg), Zeaxanthin (2mg)

This formula combines powerful antioxidants that help 20 mg LUTEIN damaging effects of free radicals and is designed by NTCM 800 mcg ZEAXANTHIN

Nature's Plus
The Zeaxanthin Specialist

Ultra MAXIMUM STRENGTH

LUTEIN

100% PURE

60 SOFTGELS

Supports Eye Health

Supplement Facts

Supplement Facts	
LUTEIN	20 mg
MESO-ZEAXANTHIN	10 mg
ZEAXANTHIN	2 mg

128 50

0 77457 49265 5

Another popular Lutein supplement Natures Plus Lutein from Marigolds which also has Zeaxanthin added.

Protect your eyes form direct sunlight by wearing UV
Sunglasses/ shields and a brimmed hat/cap. Eg. Sunshield
Wraparounds 100% UVA/B

Where to buy the vitamins?

Ocuvite Preservision - Pharmacy

Omega 3 - Supermarket / Health food shop/Pharmacy

Lutein - Health food shop/ Pharmacy

